

Management of Isolated Tumour Cells, Micrometastases and the Solitary Positive Sentinel Lymph Node in Breast Cancer

Michael Puttick, Isaac Cranshaw, Wayne Jones, Alex Ng. *Department of Surgery, Auckland City Hospital, New Zealand*

Introduction

Sentinel Lymph Node Biopsy (SLNB) is now the Gold Standard method of staging the axilla in cases of breast cancer. The finding of a positive node requires further surgery and increasing size of metastasis in the sentinel lymph node is associated with increasing likelihood of further, non-sentinel lymph node,

However, this may lead to overtreatment and an unnecessary second operation if there is a solitary positive node, micrometastases or isolated tumour cells in the sentinel node. This study reviews the use of sentinel node biopsy across the city of Auckland and examines practice where isolated tumour cells and micrometastases are found.

Methods

A review of the Auckland Breast Cancer Register was carried out. Patients were identified in whom Isolated tumour cells (ITCs) and micrometastases (MMs) were found in a sentinel node. We examined whether patients had additional axillary surgery and whether other positive nodes were found.

We also examined patients in whom only the Sentinel node or nodes were positive and compared them with patients in whom there were multiple positive nodes. We looked specifically at tumour size and tumour grade to see if it is possible to predict when only the sentinel nodes will be positive.

Auckland Breast Cancer Register

This is a Project of the Auckland Breast Cancer Study Group. Data has been collected on patients from Auckland Region since 2000 in both the public and private systems. All patients give informed consent and data is anonymous. We now achieve 90% data capture on cancers treated. Auckland is a city of 1.5 million people and is served by 3 main public hospitals, as well as smaller private institutions.

Results

Isolated Tumour Cells

51 patients had ITCs in a Sentinel Node
7 patients had ITCs and had axillary node dissection with no other positive nodes
Median no. nodes = 9 (range 6-21)

Micrometastases

63 patients had MMs in a Sentinel Node
43 patients had Micromets and had axillary node dissection with no other positive nodes
Median no. nodes = 12 (range 5-32)

Only Sentinel Nodes Positive (see graph)

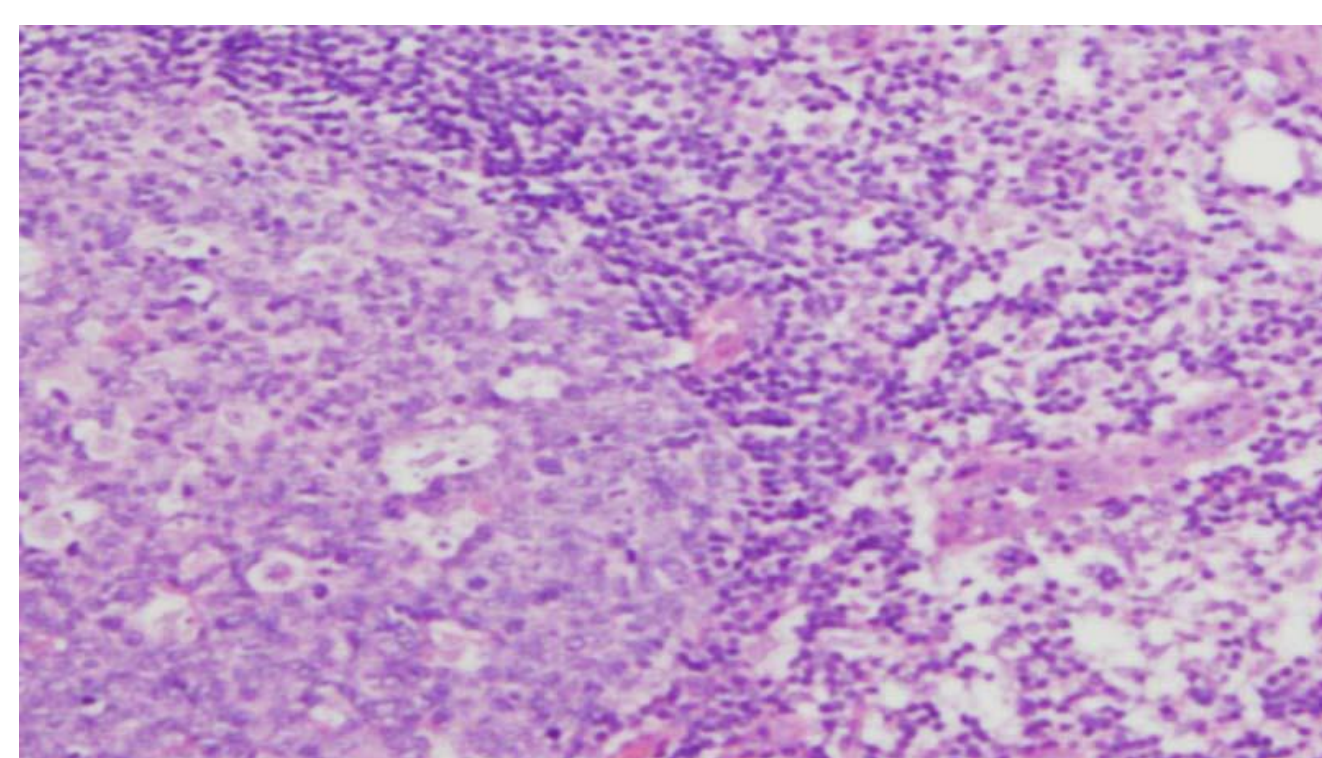
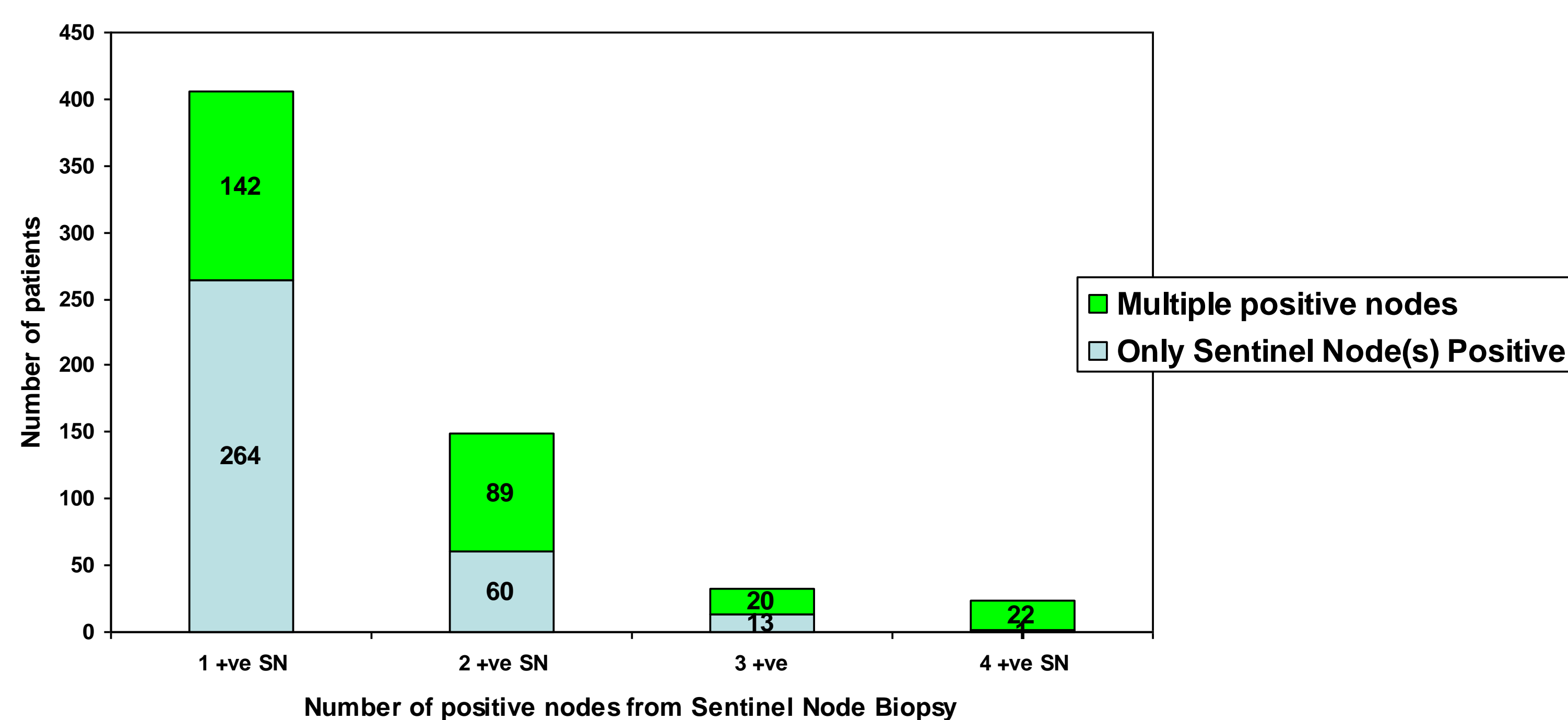
264 had single positive node and this was the only positive node
142 had single positive node and had other positive nodes at ANC

60 had 2 positive Sentinel nodes and these were the only nodes positive
89 had 2 positive SN and had other positive nodes at ANC

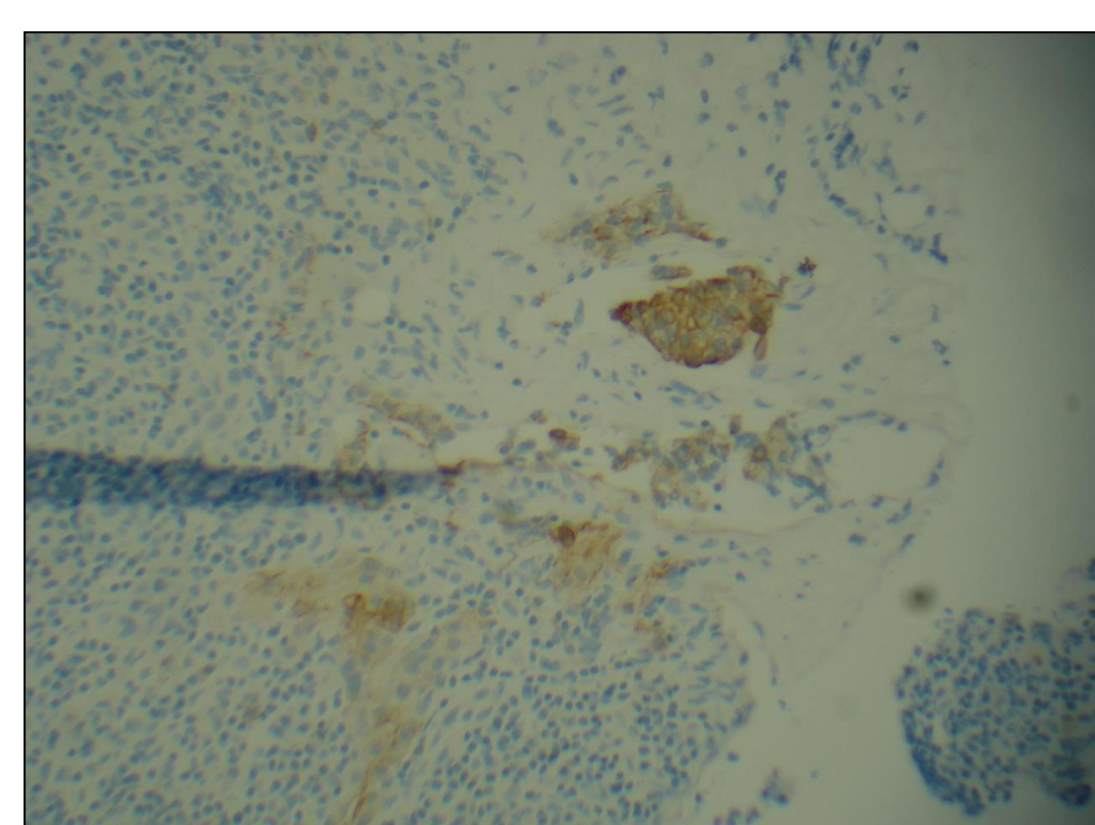
13 had 3 positive SN and these were the only positive nodes
20 had 3 positive SNs and had other positive nodes at ANC

23 had 4 positive nodes and in only 1 patient were these the only positive nodes

Graph showing Proportion of patients in whom only sentinel node(s) was positive compared with multiple positive nodes



Isolated Tumour cells (<0.2mm) in a sentinel node



Micrometastases (>0.2mm and <2mm) in a sentinel node

TUMOUR SIZE	Single +ve SN	Multiple +ve Nodes
< 5mm	1 (0.3%)	2 (0.6%)
>=5-10mm	25 (9%)	27 (8%)
>=10-20	125 (46%)	125 (39%)
>=20-50mm	111 (41%)	130 (41%)
>50	7 (3%)	35 (11%)
TOTAL	269	319

GRADE	Single +ve SN	Multiple +ve Nodes
1	52 (20%)	40 (11%)
2	141 (53%)	177 (50%)
3	71 (27%)	135 (38%)
TOTAL	264	352

No Statistical difference between the number of patients with a solitary sentinel node and multiple positive nodes with regards to tumour size and grade

Conclusions

If micrometastases or isolated tumour cells are seen in the sentinel node it is unlikely that other nodes are involved. In our series there were no instances where there were micrometastases or isolated tumour cells in a sentinel node with other nodes involved. If a single node is truly positive then it is hard to determine the status of the rest of the nodes on basis of size and grade